

## Diabetic Retinopathy

DR. (COL.) Zahiruddin Khan

Prof .Dept of Ophthalmology, Hitech Medical College & Hospital, Bhubaneswar

### **Introduction :**

Successful management of diabetic retinopathy via a combination of glucose control, Laser therapy, vitrectomy is most striking achievement of modern ophthalmology. Periodic fundus evaluation & management according to ETDRS recommendation have reduced the risk of severe visual loss less than 5%. In spite of all this, Diabetic retinopathy still remains the number one cause of new blindness in western & industrialised countries

### **Definition :**

Progressive dysfunction of the retinal blood vessels caused by chronic hyperglycemia resulting in structural damage to the neural retina.

### **Epidemiology :**

In the global scenario the number of Diabetic retinopathy is 126.6 mill (2010), estimated to grow to 191 mill (2030). The duration of Diabetes is the best predictor of DR

In Type1 diabetes, the first 5 yrs, the risk of retinopathy is very low. In 5-10 yrs duration, the risk increases to 27%. The more than 10 yrs, the risk increases to 71-90%. For a diabetes duration of >20-30 yrs, about 95% chances DR is noted (of these, 30-50% - have PDR).

In Type2 diabetes- after 11-13 yrs, the risk of retinopathy is 23%. For a duration of 16 yrs, chances increase to 60%. For a diabetes of duration more than 11 yrs, about 3% of patients had PDR. The incidence of diabetic retinopathy was more in type1 than type2. It was seen to be sight threatening in upto 10% of the patients. The prevalence of diabetes mellitus in Indian population is 66 million, of which 7 million suffer from Diabetic Retinopathy.

### **Risk Factors :**

1. Duration of diabetes onset of DM before age of 30 yrs, 50% develop Diabetic retinopathy after 10 yrs. After 30 yrs about 90% suffer from DR.
2. Poor glycemic control -High HbA1c- associated with PDR risk
3. Hypertension control beneficial especially in type2 with maculopathy
4. Females > males
5. Pregnancy may accelerate DR. Regression after delivery is seen.
6. Nephropathy- when severe, worsens DR. A control gives better response to photocoagulation.
7. Heredity -plays more role on proliferative DR
8. Hyperlipidemia, smoking, cataract sx, obesity, anemia contribute to progress of DR

### **Pathogenesis**

- 1 Aldose Reductase 1 Capillaropathy
- 1 Neovascularisation

### **Aldosereductase :**

Glucose and Galactose are converted to sorbitol & galactitol by the enzyme Aldose reductase. These two forms cannot diffuse out of the cells and their intracellular concentration increases. Due to oxidative stress there is excess of Free radicals and accumulation of glycation end products. This cycle further activates several protein kinases C isoforms and helps in disruption of ion channel function. Osmotic forces cause water to diffuse into the cells resulting in electrolyte imbalance.

### **Capillaropathy :**

Thickening of Capillary Basement Membrane,

Endothelial cell loss, loss of capillary pericytes leads to microaneurysm formation. Further changes in RBCs & leucocytes, with increased plasma viscosity and increased stickiness of platelets lead to capillary leakage, retinal haemorrhages, retinal edema and hard exudates. This causes microvascular occlusion and retinal ischaemia and AV shunting (Intraretinal microvascular anomalies) and finally neovascularisation.

**NEOVASCULARISATION:**

Capillary non perfusion leads to retinal hypoxia. This in turn causes neovascularisation mediated by VEGF, PDGF, and other angiogenic stimulators.

**CLASSIFICATION OF DIABETIC RETINOPATHY (ETDRS CLASSIFICATION)**

*Non-proliferative diabetic retinopathy*

very mild

Mild nonproliferative retinopathy

Moderate nonproliferative retinopathy

Severe nonproliferative retinopathy Very severe nonproliferative retinopathy

*Proliferative diabetic retinopathy*

Mild -moderate High risk

*Diabetic maculopathy*

Focal Diabetic Maculopathy

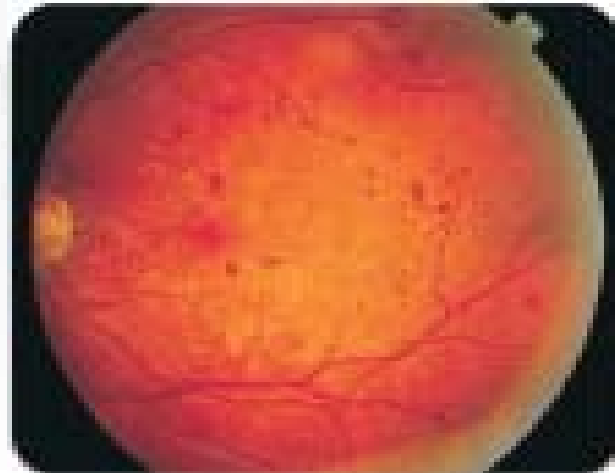
Diabetic maculopathy

Ischaemic diabetic maculopathy

*Advanced Diabetic Eye Disease*

**Terminology:**

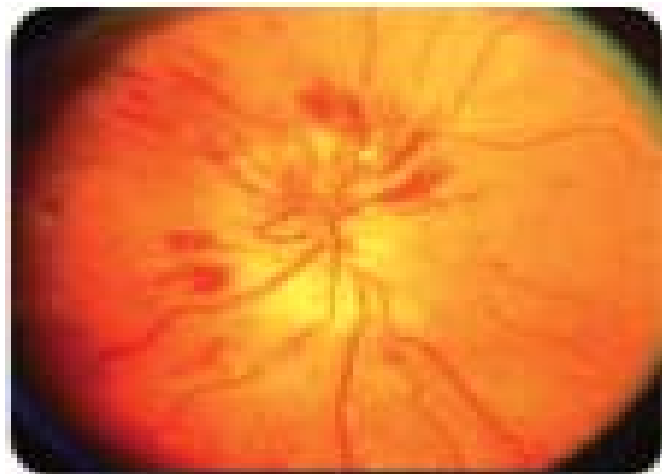
**MICRO ANEURYSM :** Tiny red dots, often initially temporal to the fovea. Tend to be the earliest signs of DR. They may be indistinguishable from dot haemorrhages. They are mostly found in inner capillary plexus (inner nuclear layer), frequently in relation to areas of capillary non-perfusion.



**MICROANEURYSM**

**RETINAL HAEMORRHAGE:**

Superficial Haemorrhages arise from the larger superficial pre-capillary arterioles forming 'flame-shaped' pattern. Intraretinal Haemorrhages are the ones arising from the venous end of capillaries and are located in the compact middle layers of the retina forming dot/blot' configuration.



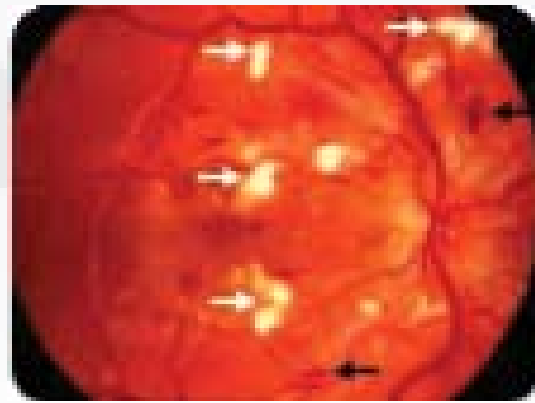
**FLAME SHAPED HAEMORRHAGE**

**EXUDATES :**

Waxy yellow lesions with relatively distinct margins, often arranged in clumps and/or rings at the posterior pole, typically surrounding leaking microaneurysms. With time number and size tend to increase.

**COTTON WOOL SPOTS :**

Cotton wool spots are composed of accumulations of neuronal debris within the nerve fibre layer. Small, whitish, fluffy superficial lesions which obscure underlying blood vessels. Clinically evident only in the post-equatorial retina, where the nerve fiber layer is of sufficient thickness to be visible.



COTTON WOOL SPOTS

**INTRARETINAL MICROVASCULAR ANOMALY (IRMA) :**

IRMAs are dilated capillaries, which seem to function as collateral channels: Fine, irregular, red intraretinal lines that run from arterioles to venules without crossing major blood vessels.

**NEW VESSELS ELSEWHERE (NVE)**

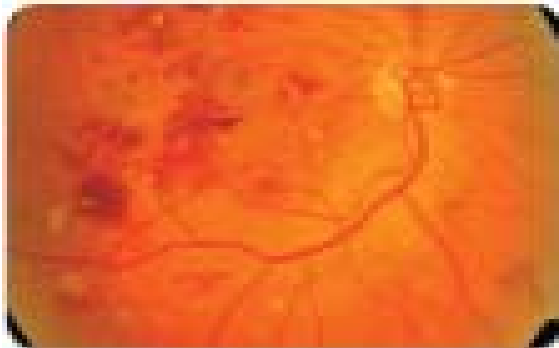
Describes neovascularization further away from the disc that may be associated with fibrosis if long-standing. It is seen along the course of major temporal retinal vessels.

**VENOUS CHANGES :**

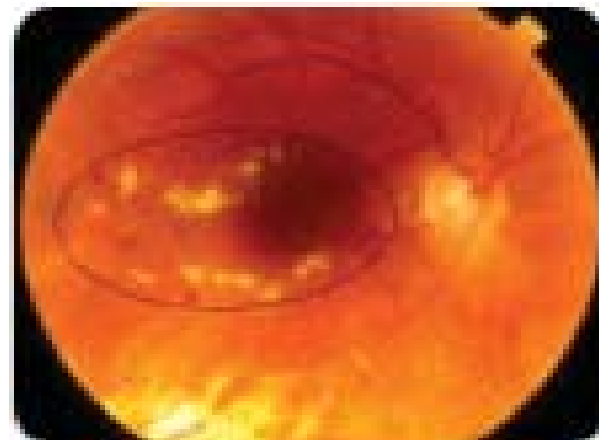
venous changes seen in ischemia as Venous Loop, Venous Segmentation 'sausage-like', Venous Beading and obliteration.

**DIABETIC MACULAR CHANGES :**

Diabetic maculopathy (foveal oedema, exudates or ischaemia) is the most common cause of visual impairment in diabetic patients, particularly type-2.



DOT & BLOT HAEMORRAHGE



HARD EXUDATES

**PROLIFERATIVE DIABETIC RETINOPATHY (PDR) :**

It has been estimated that over one-quarter of the retina must be non-perfused before PDR develop. Although preretinal new vessels may arise anywhere in the retina, they are most commonly seen at the posterior pole. Fibrous tissue, initially fine, gradually develops in association as vessels increase in size.

**NPDR :**

I. **VERY MILD** - Microaneurysm only

**NEW VESSELS AT THE DISC (NVD)**

Describes neovascularization on or within one disc diameter of the optic nerve head. These vessels leak in FFA.

II. **MILD NONPROLIFERATIVE RETINOPATHY** : Any/all of: o microaneurysm, intraretinal haemorrhage o Hard exudates / cotton wool spot (no IRMA/no sig beading)

**III. MODERATE NON-PROLIFERATIVE RETINOPATHY**

- 1 Micro aneurysms / intraretinal haemorrhages in 2 or 3 quadrants
- 1 Early mild IRMA Intra retinal Microvascular abnormalities
- 1 Sig beading in not more than 1 quad
- 1 Hard / Soft exudates may or may not be present

**III. SEVERE NONPROLIFERATIVE RETINOPATHY : Any one of the following(4-2-1 rule):**

- 1 4 quadrants of severe micro aneurysms / intraretinal haemorrhages
- 1 2 quadrant of venous bleeding
- 1 1 quadrant of IRMA changes

**IV. VERY SEVERE :** 2 or more of the criteria for severe

**PROLIFERATIVE DIABETIC RETINOPATHY :**

PDR without high risk: NVD/NVE

PDR with high risk: NVD >1/3 of disc area with/ without VH or PRH

NVD ¼ th disc area with VH or PRH

NVD > 1/2 disc area with VH with obscured NVD/E

**DIABETIC MACULOPATHY:**

**1.Focal:**

Well circumscribed retinal thickening +/- exudates

FA: late, focal hyperfluorescence due to leak, good macular perfusion

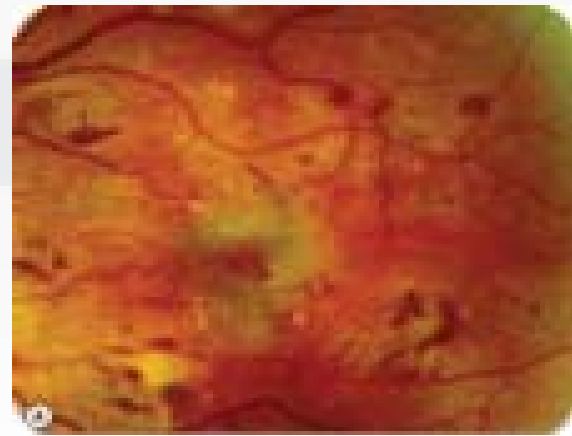
**2.Diffuse maculopathy**

Diffuse retinal thickening

+/-cystoid change

Obliteration of fovea by sev edema

FA: diff hyperfluorescence:if CMO present-



Diffuse maculopathy

>central flower petal pattern

3.Ischaemic maculopathy

Macula may look normal despite reduced V.A

PPDR +/-

FA: enlarged FAZ

Other capillary non perfusion areas

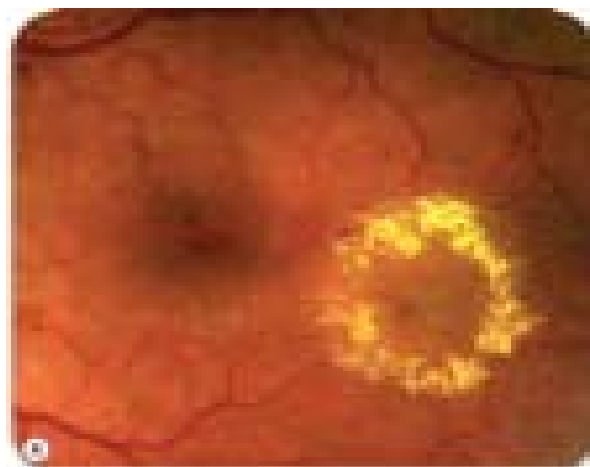
**FOCAL MACULOPATHY**

1 Well-circumscribed retinal thickening associated with complete or incomplete rings of exudates.

FA shows late, focal hyperfluorescence due to leakage, and good macular perfusion.

**DIFFUSE MACULOPATHY**

1 Diffuse retinal thickening, which may be associated with cystoid changes.-



Focal maculopathy

1 Landmarks are obliterated by severe oedema which may render localization of the fovea impossible .

FA shows late diffuse hyperfluorescence which may assume a central flower-petal pattern, if CMO is present.

### **ISCHAEMIC MACULOPATHY**

Signs are variable and the macula may look relatively normal despite reduced visual acuity. In other cases PPDR may be present .Dot and blot haemorrhages and cotton wool spots seen. Enlargement of focal avascular zone (FAZ) seen on FFA.

### **CLINICALLY SIGNIFICANT MACULAR EDEMA**

1. Thickening of retina at or within 500 micron of the centre of fovea .
2. Hard exudates at or within 500 micron of the centre of fovea associated with adjacent retinal thickening

3. Development of a zone of retinal thickening one disc diameter or larger in size, at least a part of which is within one disc diameter of foveal centre.

### **ADVANCED DIABETIC EYE DISEASE**

1. Persistent vitreous haemorrhage 2. Tractional retinal detachment 3. Neovascular glaucoma 4. Tractional retinoschisis 5. Rubeosis iridis

### **REFERENCES :**

Yanoff Duker Ophthalmology, 4th ed pg 541- 550

Ryan SJ, Schachat AP, editors Vol 2, 4th ed 2006; pg 1285 - 1322

Parson's Diseases of Eye, 22nd ed Pg 312 - 317

Kanski's Clinical Ophthalmology, 8th ed Pg 520 - 537

Science Direct Ophthalmology February 2009, Vol 116(2); 311-318